



Contents lists available at ScienceDirect

Asian Pacific Journal of Tropical Disease

journal homepage: www.elsevier.com/locate/apjtd



Document heading doi:10.1016/S2222-1808(12)60030-9

## Acute and subacute oral toxicity evaluation of *Tephrosia purpurea* extract in rodents

Talib Hussain<sup>1,2</sup>, Sheeba Fareed<sup>1</sup>, HH Siddiqui<sup>1</sup>, M Vijaykumar<sup>2</sup>, Chandana Venkateswara Rao<sup>2\*</sup><sup>1</sup>Department of Pharmacology and Toxicology, Faculty of Pharmacy, Integral University, Kursi road, Lucknow-226026, Uttar Pradesh, India<sup>2</sup>Pharmacognosy and Ethnopharmacology Division, National Botanical Research Institute (CSIR), Rana Pratap Marg, P. B. No. 436, Lucknow 226 001, Uttar Pradesh, India

## ARTICLE INFO

## Article history:

Received 15 October 2011

Received in revised form 27 December 2011

Accepted 28 February 2012

Available online 28 April 2012

## Keywords:

*Tephrosia purpurea*

Subacute toxicity

Hematological parameters

Alkaline phosphate

Total protein

Aspartate transaminase

Alanine transaminase

Alkaline phosphate

## ABSTRACT

**Objective:** To evaluate the acute and subacute toxicity of 50% ethanolic extract of *Tephrosia purpurea* (*T. purpurea*) in rodents. **Methods:** The acute toxicity test was conducted in Swiss albino mice. The extract of *T. purpurea* was administered in single doses of 50, 300 and 2000 mg/kg and observed for behavioral changes and mortality, if any. In subacute toxicity study, Wistar rats of either sex were administered two doses of *T. purpurea* i.e., 200 and 400 mg/kg (One-tenth and one-fifth of the maximum tolerated dose), p.o. for 4 weeks. During 28 days of treatment, rats were observed weekly for any change in their body weight, food and water intake. At the end of 28 days, rats were sacrificed for hematological, biochemical and histopathology study. **Results:** In the acute toxicity study, *T. purpurea* was found to be well tolerated upto 2000 mg/kg, produced neither mortality nor changes in behavior in mice. In subacute toxicity study, *T. purpurea* at dose level of 200 and 400 mg/kg did not produce any significant difference in their body weight, food and water intake when compared to vehicle treated rats. It also showed no significant alteration in hematological and biochemical parameters in experimental groups of rats apart from a decrease in aspartate transaminase, alanine transaminase and alkaline phosphate content at the dose of 400 mg/kg. Histopathological study revealed normal architecture of kidney and liver of *T. purpurea* treated rats. **Conclusions:** These results demonstrated that there is a wide margin of safety for the therapeutic use of *T. purpurea* and further corroborated the traditional use of this extract as an anti hepatocarcinogenic agent.

### 1. Introduction

*Tephrosia purpurea* (*T. purpurea*) (Linn.) Pers. (Leguminosae) is a copiously branched herbaceous perennial plant distributed throughout the tropics and commonly known as sarponkha in India. According to Ayurveda literature this plant is also called "Sarwa wranvishapaka" which means that it has the property of healing all types of wounds[1]. The plant has been used in the treatment of bronchitis, diuretic, bilious febrile attack, boils, pimples, tonic, laxative, cough, lightness of the chest, tumour and in biliary and splenic troubles also[2]. The leaves are reported to be useful in jaundice[3]. It is an important component of some preparations such as Tephroli and Yakrifit used for liver disorders, available in

Indian market. *T. purpurea* is rich in prenylated flavonoids including flavones, flavanones, chalcones and rotenoids[4]. Despite the wide use of *T. purpurea* in folk medicine, no study has been published in the scientific literature about its toxicological profile. Therefore, efforts are now being made in our laboratories to define its preclinical activity and safety profile necessary for further development of the extract. The present communication summarizes the acute and subacute oral toxicity of the 50% aqueous ethanolic extract of *T. purpurea* in experimental animals.

### 2. Materials and methods

#### 2.1. Plant material and extraction

The fresh plant of *T. purpurea* was collected in the botanical garden of National Botanical Research Institute, India in November 2009. The plant material was identified and authenticated and the voucher specimen number (NAB

\*Corresponding author: Chandana Venkateswara Rao, Pharmacognosy and Ethnopharmacology Division, National Botanical Research Institute (CSIR), Rana Pratap Marg, P. B. No. 436, Lucknow 226 001, Uttar Pradesh, India.

Tel: +91 522 2297976

Fax: +91 522 2205836

E-mail: mdth\_ah@yahoo.com

200497) was deposited in the departmental herbarium. The coarsely powdered material was exhaustively extracted thrice with 50% aqueous ethanol; the yield of *T. purpurea* was 6.28% (w/w). The high performance thin layer chromatography studies of the *T. purpurea* along with rutin (SD Fine–Chem Ltd, Mumbai) were carried on pre-coated silica gel plate (Merck 60 F254) as the stationary phase and ethyl acetate: formic acid: acetic acid: water (100:11:11:27) as the mobile phase. These plates were observed at UV light at 254 nm and were scanned on TLC scanner III using winCAT software. The yield of rutin was found to be 1.47%.

## 2.2. Animals

Wistar albino rats (150–170 g) and Swiss albino mice (25–30 g) procured from Central Drug Research Institute, Lucknow, India of both sexes were housed separately in polypropylene cage at temperature of  $(22 \pm 2) ^\circ\text{C}$  and 50–60% relative humidity, with a 12 h light/dark cycle respectively, for one week before and during the experiment. Animals were allowed to access standard rodent pellet diet (Dayal animal feed, India) and drinking water. Food was withdrawn for overnight before the experiment though water was allowed *ad libitum* and allocated to different experimental groups. The dosing volume was not exceeded 1 mL/100g body weight. All studies were performed in accordance with the guide for the care and use of laboratory animals, as adopted and promulgated by the Institutional Animal Care Committee, CPCSEA, India (Reg. No. 1213/ac/2008/CPCSEA/IU).

## 2.3. Acute toxicity study

Acute oral toxicity of the 50% aqueous ethanolic extract of *T. purpurea* was evaluated in Swiss albino mice of either sex (25–30 g), as per OECD guideline (Organization for Economic Co-operation and Development, Guideline-423, adopted on 17th December, 2001) with slight modifications. Twenty four animals were equally divided into four groups ( $n=6$ ) as per sex. The extract was administered in 0.3% carboxy-methyl cellulose (CMC) suspension at doses of 50, 300 and 2000 mg/kg, whereas the control group received the CMC suspension only. Food or water was withheld for a further 1–2 hours after drug administration. Mice were closely observed for the initial 4 h after the administrations, and then once daily during the following days. The behavioural changes closely observed for were: hyperactivity, ataxia, tremors, convulsions, salivation, diarrhoea, lethargy, sleep and coma. Total observation period for eventual mortality was 14 days<sup>[5]</sup>. One-tenth and one-fifth of the maximum tolerated dose of the extract (2000 mg/kg) tested for acute toxicity was selected for the subacute toxicity study *i.e.*, 200 and 400 mg/kg.

## 2.4. Subacute toxicity study

Thirty rats (150–170 g) were randomly assigned into three groups ( $n=10$  or  $n=5/\text{sex}$ ), five females (nulliparous and non-pregnant) and five males were housed separately as per sex in each group. OECD guideline was followed during the study with slight modifications. Treatments were administered orally once a day for 4 weeks. The Group I rats served as control, Group II and III received *T. purpurea* at doses of 200 and 400 mg/kg (One-tenth and one-fifth of the maximum tolerated dose), respectively. All rats were observed daily for

physiological and behavioural changes. Rat that died during the test period was tested pathologically, and all animals were examined at the end of the test period.

## 2.5. Observation and examination methods

Clinical signs were observed at least once a day during 28 days of dosing. Body weights, water and food intake were measured once a week by using digital Feeding and Drinking Analyser (Ugo basile, 41700, Italy). They were fasted overnight prior to blood collection by retro-orbital technique on 29th day of the study. Hematological analysis was performed using an automatic hematology analyzer (Medonic CA620, Boule, Sweden). The parameters included: red blood cell (RBC) count, hemoglobin (Hb), hematocrit (Ht), mean corpuscular volume (MCV), mean corpuscular haemoglobin (MCH), mean corpuscular haemoglobin concentration (MCHC), platelets (PLT), leukocyte (WBC) count, neutrophil, eosinophil, basophil, lymphocyte and monocyte counts. For biochemical analysis, blood was centrifuged at 3000 rpm for 10 min. Serum was separated and assayed by using diagnostic kits for glucose, creatinine, blood urea nitrogen (BUN), total bilirubin (TB), aspartate transaminase (AST), alanine transaminase (ALT), alkaline phosphate (ALP), total cholesterol (TC), total protein (TP) and albumin (ALB). After blood collection, animals were sacrificed for isolation of kidney and liver to observe histopathological changes, if any. The kidney and liver were dissected out and were fixed in 10% formalin solution. Paraffin sections were made and stained with haematoxylin and eosine for detailed histopathology study<sup>[6]</sup>. The values were represented as mean  $\pm$  SEM. Analysis of variance (ANOVA) test was followed by individual comparison by Newman–Keuls test using Prism Pad software (version 3.0) for the determination of level of significance. The *P*-values of  $<0.05$  are considered significant for the experiment.

## 3. Result

### 3.1. Acute toxicity study

Mice administered with *T. purpurea* upto 2000 mg/kg did not show any kind of abnormal behaviour, during initial 4 h after drug administration. No mortality was observed during 14 days after treatment with *T. purpurea* in either sex.

### 3.2. Subacute toxicity study

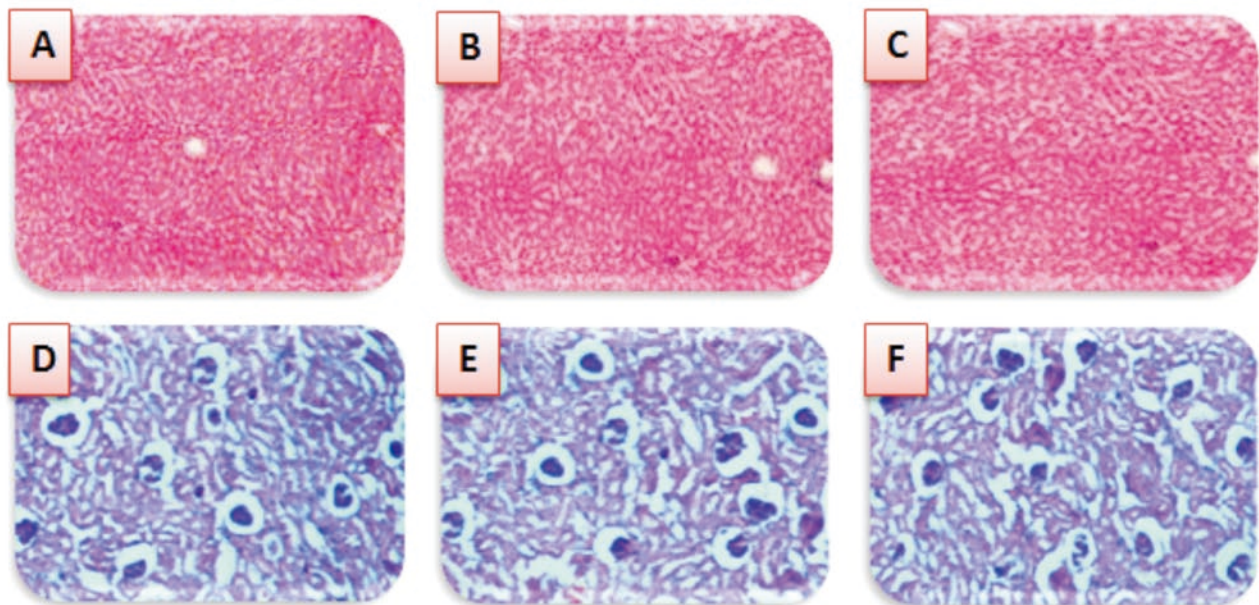
No significant differences either in control or *T. purpurea* treated group of both sexes were noticed in body weight, food and water intake (data not shown). As summarised in Table 1, extract treatments did not significantly change the level of RBC, Hb, Ht, MCV MCH, MCHC, PLT, WBC and DLC. It is apparent from Table 2 that the serum levels of glucose, creatinine, BUN, TB, TC, TP and albumin were not altered while AST, ALT, ALP content was slightly decreased in group III rats, however it was within the normal range. Histopathological features of control and *T. purpurea* treated (200 and 400 mg/kg) rats revealed the absence of any gross pathological lesion in kidney and liver (Figure 1).

**Table 1**Effect of *T. purpurea* on hematological parameters of rats in subacute toxicity (mean±SEM, n= 10).

Parameters	Control group	<i>T. purpurea</i> treated group	
		200 mg/kg	400 mg/kg
RBC ( $\times 10^6/\mu\text{L}$ )	8.24 ± 0.35	8.92 ± 0.87	9.27 ± 1.13
Hb (g/dL)	15.12 ± 1.02	15.82 ± 0.97	15.71 ± 1.08
Ht (%)	49.41 ± 2.45	51.63 ± 3.34	51.37 ± 3.61
PLT ( $\times 10^3/\mu\text{L}$ )	806.20 ± 89.73	833.5 ± 87.81	787.74 ± 76.38
MCV (fL)	51.21 ± 5.04	50.06 ± 4.32	51.61 ± 5.41
MCH (pg)	17.96 ± 1.23	19.12 ± 2.21	18.15 ± 1.76
MCHC (g/dL)	35.41 ± 3.51	34.36 ± 4.72	36.17 ± 4.12
WBC ( $\times 10^3/\mu\text{L}$ )	7.27 ± 1.34	7.59 ± 1.37	6.89 ± 0.93
Neutrophils (%)	23.61 ± 2.13	22.93 ± 3.74	24.79 ± 3.64
Eosinophils (%)	1.47 ± 0.55	1.65 ± 0.62	1.23 ± 0.45
Basophils (%)	0.00 ± 0.00	0.00 ± 0.00	0.00 ± 0.00
Lymphocyte (%)	69.82 ± 6.53	67.96 ± 6.54	66.34 ± 6.28
Monocyte (%)	2.00 ± 0.48	1.46 ± 0.39	1.44 ± 0.32

**Table 2**Effect of *T. purpurea* on blood chemistry values of rats in subacute toxicity (mean±SEM, n= 10).

Parameters	Control group	<i>T. purpurea</i> treated group	
		200 mg/kg	400 mg/kg
Glucose (mg/dL)	72.54 ± 6.27	68.42 ± 7.53	66.32 ± 8.43
Creatinine (mg/dL)	0.91 ± 0.06	0.89 ± 0.05	0.93 ± 0.03
BUN (mg/dL)	19.27 ± 1.76	18.54 ± 1.09	17.86 ± 1.83
TB (mg/dL)	0.69 ± 0.05	0.67 ± 0.06	0.62 ± 0.07
AST (U/L)	135.4 ± 7.32	121.3 ± 6.33	119.3 ± 6.17
ALT (U/L)	38.21 ± 3.56	32.11 ± 2.65	30.15 ± 2.29*
ALP (U/L)	79.35 ± 4.43	70.65 ± 4.32	66.38 ± 4.36
TC (mg/dL)	56.86 ± 5.77	57.61 ± 5.68	55.84 ± 5.21
TP (g/dL)	8.41 ± 0.23	7.94 ± 0.23	7.58 ± 0.78
Albumin (g/dL)	2.66 ± 0.08	2.74 ± 0.07	2.76 ± 0.06

\* $P < 0.05$  compared with respective control group.**Figure 1.** Histopathological picture of liver and kidney of control and experimental group of animals.

(A) The section of liver from control animals revealed normal architecture and hepatic cells with granulated cytoplasm; (B) and (C) The section of liver from *T. purpurea* 200 and 400 mg/kg exhibited normal architecture of hepatocytes indicating the safe nature of the extract. (D) The section of kidney from control animals showed normal size of glomeruli with normal tubules; (E) and (F) The section of kidney from *T. purpurea* 200 and 400 mg/kg exhibited within the limits of normalcy.

#### 4. Discussion

The use of herbal medicines as alternative treatments has been increasing worldwide, and medicinal plants may have biological activities that are beneficial to mankind[7]. Since no reports on toxicity and safety profile of *T. purpurea* extract is yet available, it was considered necessary to have some information on toxicity potential of the extract tested to maximize their benefits. Observations made during our efforts in the oral acute toxicity studies showed the lack of mortality and toxicity upto oral treatment of 2000 mg/kg body weight, which suggests that the *T. purpurea* is practically nontoxic at single dose. For subacute toxicity study the higher dose level of 400 mg/kg (1/5th of the maximum tolerated dose) and low dose level of 200 mg/kg (1/10th of the maximum tolerated dose) were selected. The 50% aqueous ethanolic extract of *T. purpurea* at the doses used did not produce any marked changes in experimental groups of rats, as evidenced by the absence of toxic symptoms, no changes in water/food ingestion and body weight. Analysis of blood parameters is relevant to risk evaluation as the changes in the haematological system have a higher predictive value for human toxicity, when the data are translated from animal studies[8–16]. No significant alterations in the haematological parameters of treated rats can be attributed to the plant extract. The normal values of the renal biochemical parameters such as blood urea nitrogen and creatinine suggest that the extract does not produce any sort of disturbance in the renal function, as has been found in case of various plant extracts and hence is safe on its chronic use in various diseases.

Subacute administration of *T. purpurea* did not cause any significant change in serum glucose level TC, TB, TP and ALB. However, liver enzymes (AST, ALT and ALP) were decreased at higher dose but the magnitude is too small to have biological relevance. The increase levels of AST, ALT and ALP in the blood are associated with structural and functional dysfunction of hepatocellular membrane damage of hepatic cells[17]. These observations of decrease in the levels of liver enzymes might be due to the presence of hepatoprotective agents in the extract. These results are in support of the previous studies and decrease of hepatic enzymes levels need to be further investigated[18]. Therefore our ongoing research work is directed towards identifying an herbal anti-hepatocarcinogenic agent. Moreover, histopathological observations correlate the other results showing the normal cellular architectures in the *T. purpurea* treated (200 and 400 mg/kg) group of animals, without any necrosis or fatty infiltration, which can substantiate the safety profile of the extract at this dose level. Present observations indicate for the first time that 50% hydroalcoholic extract of *T. purpurea* have a broad safety margin in experimental animals commonly used in *in vivo* experimental and preclinical pharmacological studies.

#### Conflict of interest statement

We declare that we have no conflict of interest.

#### Acknowledgements

The authors would like to acknowledge gratefully the efficient help extended by the Director of National Botanical Research Institute (CSIR) for providing necessary facilities for this research work.

#### References

- [1] Deshpande SE, Shah GB, Parmar NS. Antiulcer activity of *Tephrosia purpurea* in rats. *Indian J Pharmacol* 2003; **35**: 168–172.
- [2] Trivedi PC. *Ethnomedicinal plants of Indian*. Jaipur, India: Aavishkar Publisher and Distributors; 2007, p. 176.
- [3] Joshi SG. *Medicinal plants*. New delhi, India: Oxford and IBH Publishing Private Limited; 2007, p. 211.
- [4] Mohamed–Elamir FH, Mohamed HA, Fumihiro N, Yoshinori A, Paul WP. Rare prenylated flavonoids from *Tephrosia purpurea*. *Phytochem* 2009; **70**: 1474–1477.
- [5] Sim KS, SriNurestri AM, Sinniah SK, Kim KH, Norhanom AW. Acute oral toxicity of *Pereskia bleo* and *Pereskia grandifolia* in mice. *Pharmacog Magaz* 2010; **6**: 67–70.
- [6] Singh A, Dubey SD, Patne S, Kumar V. Acute and sub-chronic toxicity study of calcium based Ayurvedic ‘Bhasmas’ and a ‘Pishti’ prepared from marine-sourced animals. *J Herb Med Toxicol* 2010; **4**: 35–47.
- [7] Rosidah Yam MF, Sadikun A, Ahmad M, Akowuah GA, Asmawi MZ. Toxicology evaluation of standardized methanol extract of *Gynura procumbens*. *J Ethnopharmacol* 2009; **123**: 244–249.
- [8] Olson H, Betton G, Robinson D, Thomas K, Monro A, Kolaja G, et al. Concordance of toxicity of pharmaceuticals in humans and in animals. *Regul Toxicol Pharmacol* 2000; **32**: 56–67.
- [9] Hossain S, Kader G, Nikkon F, Yeasmin T. Cytotoxicity of the rhizome of medicinal plants. *Asian Pac J Trop Biomed* 2012; **2**: 125–127.
- [10] Kiran PM, Raju AV, Rao BG. Investigation of hepatoprotective activity of *Cyathia gigantea* (Wall. ex. Hook.) leaves against paracetamol-induced hepatotoxicity in rat. *Asian Pac J Trop Biomed* 2012; **5**: 352–356.
- [11] Jain M, Kapadia R, Jadeja RN, Thounaojam MC, Devkar RV, Mishra SH. Cytotoxicity evaluation and hepatoprotective potential of bioassay guided fractions from *Feronia limmonia* Linn leaf. *Asian Pac J Trop Biomed* 2011; **1**: 443–447.
- [12] Badakhshan MP, Sreenivasan S. *In vivo* toxicity study of *Lantana camara*. *Asian Pac J Trop Biomed* 2011; **1**: 230–232.
- [13] Johnkennedy N, Adamma E. The protective role of *Gongronema latifolium* in acetaminophen induced hepatic toxicity in Wistar rats. *Asian Pac J Trop Biomed* 2011; **1**(Suppl 2): S151–S154.
- [14] Rathee P, Rathee D, Rathee D, Rathee S. *In-vitro* cytotoxic activity of  $\beta$ -Sitosterol triacetonate isolated from *Capparis decidua* (Forsk.) Edgew. *Asian Pac J Trop Med* 2012; **5**: 225–230.
- [15] RK Gupta, T Hussain, G Panigrahi, A Das, GN Singh, K Sweety, et al. Hepatoprotective effect of *Solanum xanthocarpum* fruit extract against CCl<sub>4</sub> induced acute liver toxicity in experimental animals. *Asian Pac J Trop Med* 2012; **4**: 964–968.
- [16] Thirumalai T, David E, Vивиyan Therasa S, Elumalai EK. Restorative effect of *Eclipta alba* in CCl<sub>4</sub> induced hepatotoxicity in male albino rats. *Asian Pac J Trop Med* 2012; **4**: 304–307.
- [17] Burger C, Fischer DR, Cordenunzi DA, Batschauer APB, Filho VC, Soares ARS. Acute and subacute toxicity of the hydroalcoholic extract from *Wedelia paludosa* (*Acmela brasiliensis*) (Asteraceae) in mice. *J Pharmacol Pharm Sci* 2005; **8**: 370–373.
- [18] Amit K, Arun G, Shyam SA. Evaluation of hepatoprotective activity of aerial parts of *Tephrosia purpurea* and stem bark of *Tecomella undulata*. *J Ethnopharmacol* 2009; **122**: 1–5.