



Contents lists available at [ScienceDirect](http://ScienceDirect.com)

## Asian Pacific Journal of Tropical Disease

journal homepage: [www.elsevier.com/locate/apjtd](http://www.elsevier.com/locate/apjtd)



Case report doi: 10.1016/S2222-1808(16)61104-0

©2016 by the Asian Pacific Journal of Tropical Disease. All rights reserved.

### Intrahepatic ascariasis – Common parasite at an uncommon site

Udit Chauhan<sup>1\*</sup>, Neeraj Jain<sup>1</sup>, Sunil Kumar Puri<sup>1</sup>, Lalit Garg<sup>1</sup>, Monika Singh<sup>2</sup>

<sup>1</sup>Department of Radiology, Gobind Ballabh Pant Institute of Post Graduate Medical Education and Research, New Delhi, 110002, India

<sup>2</sup>Department of Pathology, Dr RML Hospital, New Delhi, India

#### ARTICLE INFO

##### Article history:

Received 14 Mar 2016

Received in revised form 4 Apr, 2nd revised form 5 Apr, 3rd revised form 1 Jun 2016

Accepted 25 Jun 2016

Available online 15 Jul 2016

##### Keywords:

Intrahepatic  
Ascariasis  
Parasite  
Biliary  
Cholangitis

#### ABSTRACT

Bacterial infections of the biliary tree are common infections of the biliary system which frequently lead to life-threatening sepsis. Parasitic infections of the biliary tree like ascariasis are not uncommon. Most adult worms reside into the extrahepatic biliary system. Intrahepatic existence is not commonly described. Urgent recognition of the intrahepatic existence of this common parasite is of paramount importance in order to start timely treatment of this life-threatening infection. Authors described a case of intrahepatic ascariasis in a young male who was diagnosed radiologically and thereafter managed with endoscopic retrograde cholangio-pancreatography and antibiotics.

## 1. Introduction

Biliary infections and biliary cholangitis are common terms used to define infections of the biliary tree. Bacteria are the most common cause for these infections. Parasites can form an important group of biliary infections and act as causative agents or may predispose bacterial infections. Despite being an important cause, these infections are quite uncommon to find, especially in the intrahepatic biliary system[1]. Ascariasis is a common infection in the tropical and subtropical countries[2]. Intrahepatic extension of this parasite through the extrahepatic biliary system is uncommon. Ascariasis is generally diagnosed on basis of faecal examination. However, diagnosing intrahepatic ascariasis is challenging. Fortunately, ultrasonography plays a pivotal role in recognising this infection[3]. Imaging recognition of intrahepatic biliary ascariasis is an important

issue in order to achieve immediate diagnosis and provide urgent treatment to avoid fatal complications.

## 2. Case report

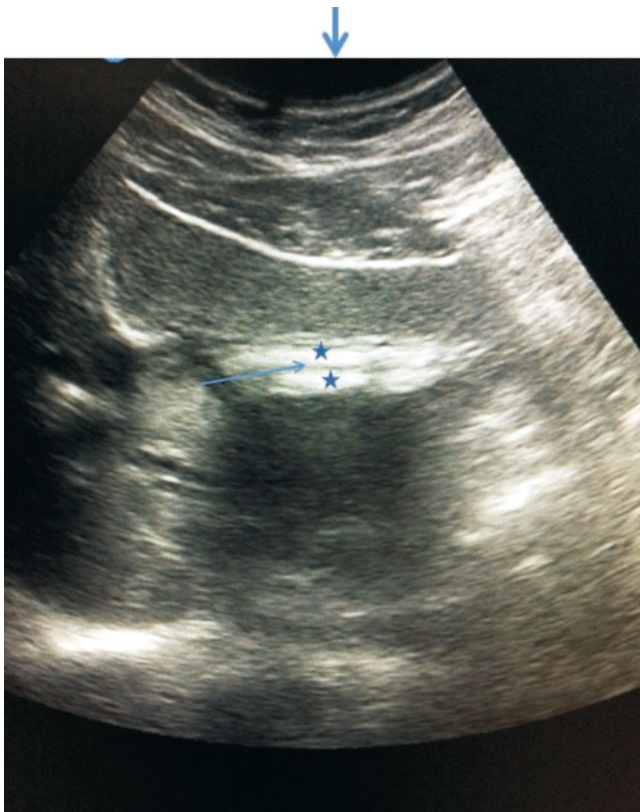
A 35-year-old male presented to the emergency department with complaints of fever with chills and rigor for one day in addition to pain abdomen. The patient was pale and dehydrated. Laboratory examinations revealed raised total bilirubin (7 mg/dL) (direct 5.5 mg/dL and indirect 1.5 md/dL) and serum alkaline phosphatase (759 IU/L). Aspartate transaminase and alanine transaminase were within the higher side of the normal range. Ultrasound examination was done, which revealed left lobar intrahepatic biliary dilatation (IHBRD) displaying two linear parallel echogenic filling defects with hypochoic centre in segment II bile duct (Figure 1). Common bile duct showed clear non-dilated lumen. Contrast-enhanced computed tomography revealed a cast-like elongated mildly hyperdense material in segment II with IHBRD (Figure 2). A diagnosis of intrahepatic ascariasis was suggested. The patient was subjected to endoscopic retrograde cholangio-pancreatography (ERCP) followed by stent placement and was given praziquantel to eradicate the infestation. Presently, the patient is healthy and has recovered from cholangitis and jaundice.

\*Corresponding author: Udit Chauhan, Department of Radiology, Gobind Ballabh Pant Institute of Post Graduate Medical Education and Research, New Delhi, 110002, India.

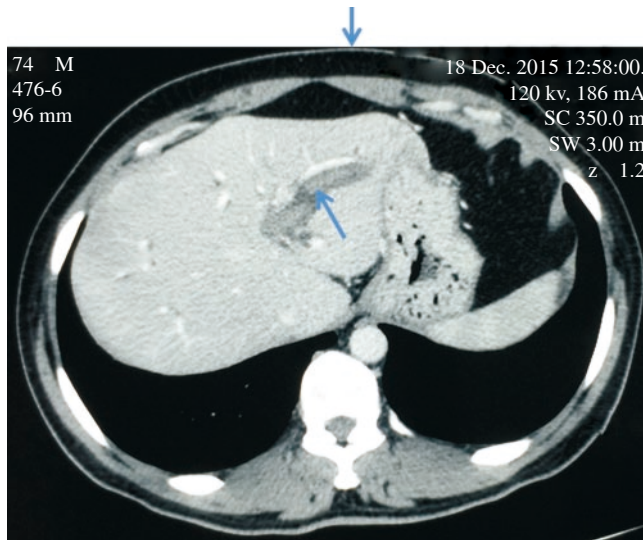
Tel: +919968760276

E-mail: [dr.udit.chauhan@gmail.com](mailto:dr.udit.chauhan@gmail.com)

The journal implements double-blind peer review practiced by specially invited international editorial board members.



**Figure 1.** Ultrasound image displaying linear echogenic parallel lines (star) in the left lobar bile duct with hypoechoic central lumen (arrow) suggestive of worm.



**Figure 2.** Contrast-enhanced computed tomography of abdomen reveals linear hyperdense lesion (arrow) filling the intrahepatic bile duct with associated IHBRD suggestive of worm.

### 3. Discussion

Biliary ascariasis is not uncommon in the tropical and subtropical countries. This presentation of biliary ascariasis includes biliary colic (56%), acute cholangitis (25%), acute cholecystitis (13%), acute pancreatitis (6%) and rarely hepatic abscess or haemobilia[4-6].

Amongst the laboratory markers, there could be elevation of bilirubin, transaminases and alkaline phosphatase.

Diagnosis of ascariasis is mainly dependent on the detection

of parasite in stool or duodenal contents. However, these may be negative at many times. Ultrasonography can be of great help in diagnosing these. Ultrasound typically shows the parasite as tubular structure with echogenic lines without posterior acoustic shadowing and displaying a hypoechoic centre[7,8]. Computed tomography also shows the parasite as mildly hyperdense filling defect. However, sometimes non specific indirect signs may be seen like biliary dilatation or abscess formation which may complicate the matter by confusing them with malignancy or stones[9].

Intrahepatic ascariasis is an uncommon infection which needs early recognition in order to avoid fatal outcomes. Imaging provides important diagnostic clues for this and helps in planning the adequately timed treatment. When patients present with cholangitis biliary drainage and antibiotics are the main stay of treatment instead of removing the parasite. Once the acute episode of cholangitis settles, ascariasis could be eradicated with medications like praziquantel, ERCP and even surgery.

The parasite must be eradicated in order to prevent recurrent cholangitis and hepatolithiasis. Serial ultrasound examinations are helpful to monitor the effect of medical therapy. Surgery is reserved for ERCP failure cases[10,11].

### Conflict of interest statement

We declare that we have no conflict of interest.

### References

- [1] Boey JH, Way LW. Acute cholangitis. *Ann Surg* 1980; **191**(3): 264-70.
- [2] Bethony J, Brooker S, Albonico M, Geiger SM, Loukas A, Diemert D, et al. Soil-transmitted helminth infections: ascariasis, trichuriasis, and hookworm. *Lancet* 2006; **367**(9521): 1521-32.
- [3] Das CJ, Kumar J, Debnath J, Chaudhry A. Imaging of ascariasis. *Australas Radiol* 2007; **51**(6): 500-6.
- [4] Keating A, Quigley JA, Genterola AF. Obstructive jaundice induced by biliary ascariasis. *BMJ Case Rep* 2012; doi: 10.1136/bcr-2012-007250.
- [5] Klimovskij M, Dulskas A, Kraulyte Z, Mikalauskas S. Ascariasis of the pancreatic duct. *BMJ Case Rep* 2015; doi: 10.1136/bcr-2014-207936.
- [6] Alam S, Mustafa G, Rahman S, Kabir SA, Rashid HO, Khan M. Comparative study on presentation of biliary ascariasis with dead and living worms. *Saudi J Gastroenterol* 2010; **16**(3): 203-6.
- [7] Jethwani U, Singh GJ, Sarangi P, Kandwal V. Laproscopic management of wandering biliary ascariasis. *Case Rep Surg* 2012; **2012**: 561563.
- [8] Sharma M. Echogenic shadow in the common bile duct. Diagnosis: biliary ascariasis. *Gastroenterology* 2011; **141**(1): e14-5.
- [9] Hwang CM, Kim TK, Ha HK, Kim PN, Lee MG. Biliary ascariasis: MR cholangiography findings in two cases. *Korean J Radio* 2001; **2**(3): 175-8.
- [10] Shah OJ, Zargar SA, Robbani I. Biliary ascariasis: a review. *World J Surg* 2006; **30**(8): 1500-6.
- [11] Astudillo JA, Sporn E, Serrano B, Astudillo R. Ascariasis in the hepatobiliary system: laparoscopic management. *J Am Coll Surg* 2008; **207**(4): 527-32.