




Contents lists available at [ScienceDirect](http://www.sciencedirect.com)

Asian Pacific Journal of Tropical Disease

journal homepage: www.elsevier.com/locate/apjtd



Case report doi: 10.1016/S2222-1808(16)61122-2

©2016 by the Asian Pacific Journal of Tropical Disease. All rights reserved.

Red eye in cat lovers: Case series of Parinaud's oculoglandular syndrome

Munirah Abd Rashid, Teik June Ling, Mushawiahti Mustapha*, Hazlita Mohd Isa

Department of Ophthalmology, Universiti Kebangsaan Malaysia Medical Centre, National University of Malaysia, Jalan Yaacob Latiff, 56000, Cheras, Kuala Lumpur, Malaysia

ARTICLE INFO

Article history:

Received 13 Jun 2016

Received in revised form 8 Jul 2016

Accepted 20 Jul 2016

Available online 16 Aug 2016

Keywords:

Cat-scratch disease

Bartonella henselae

Conjunctivitis

Lymph nodes

ABSTRACT

Parinaud's oculoglandular syndrome (POS) is an atypical manifestation of cat-scratch disease. Many reported cases of POS are secondary from *Bartonella henselae* but none has been reported from Southeast Asian region. This case series report two cases of POS. Both cases presented with unilateral granulomatous conjunctivitis and ipsilateral periauricular lymph node swelling. Both had positive history of contact with cats. One patient was treated with oral ciprofloxacin for two weeks while the another patient was treated with oral azithromycin for six weeks. Both cases recovered well.

1. Introduction

Parinaud's oculoglandular syndrome (POS) commonly caused by *Bartonella henselae* (*B. henselae*) is an atypical form of cat-scratch disease[1]. The prodromal period is within 3–10 days from the inoculation time to the development of symptoms[2]. Patients usually presented with low grade fever, malaise, fatigue and papular skin lesion[1]. Tender and swollen lymphadenopathy is a classic presentation which commonly involves the preauricular and submandibular region[1].

Unilateral granulomatous conjunctivitis usually occurs in young children less than ten years old[2]. ELISA is one of the most available methods to detect *B. henselae*[2]. Cat-scratch disease is commonly self-limited. However, in a prolonged condition, antibiotic is recommended. Options are azithromycin, clarithromycin, ciprofloxacin, doxycycline and rifampicin[2,3]. Due to its rare incidence and lack of reporting from our region, we are presenting two case series from our center. Despite its nature of good visual

outcome, it is important to recognize its characteristic presentation to avoid unnecessary anxiety for conjunctivitis with prolonged resolution.

2. Case report

2.1. Case 1

A 14-year-old healthy Malay girl presented with left eye redness associated with tearing for 1 week. There was also painful ipsilateral pre-auricular swelling. She had one-day history of fever prior to the ocular symptom. There was no cough, loss of weight nor appetite. Examination of the left eye revealed best corrected visual acuity of 6/9. The conjunctiva was diffusely injected and chemotic with no corneal lesion (Figure 1). There was an area of multiple granulomatous nodular swelling with central creamy lesion over the nasal aspect of the palpebral conjunctiva (Figure 2). Pre-auricular lymph node was also enlarged up to 10 cm and tender. Patient's family had a cat as a pet. However, there was no significant history of cat scratch event and the patient claimed she herself was not a cat lover. Therefore, she had the least contact with the cat in her family house. Chloramphenicol eye drops were initially prescribed by a general practitioner with worsening of symptoms and signs. Serology of *B. henselae* was tested by ELISA, which revealed an elevated level of immunoglobulin G and immunoglobulin M. Investigations for *M. tuberculosis* by Mantoux test and chest

*Corresponding author: Mushawiahti Mustapha, Department of Ophthalmology, Universiti Kebangsaan Malaysia Medical Centre, National University of Malaysia, Jalan Yaacob Latiff, 56000, Cheras, Kuala Lumpur.

Tel: +603 91455981

E-mail: drmusha@gmail.com

Foundation Project: Supported by Universiti Kebangsaan Malaysia with the grant number of FF-2016-157.

The journal implements double-blind peer review practiced by specially invited international editorial board members.

radiograph were negative. Venereal Disease Research Laboratory testing to look for *T. pallidum* was also negative. She was treated with 2 weeks of oral ciprofloxacin and topical moxifloxacin eye drops. Resolution took more than 2 weeks with slow improvement of the conjunctival lesion and swelling (Figure 3). Visual acuity remained good at 6/9.

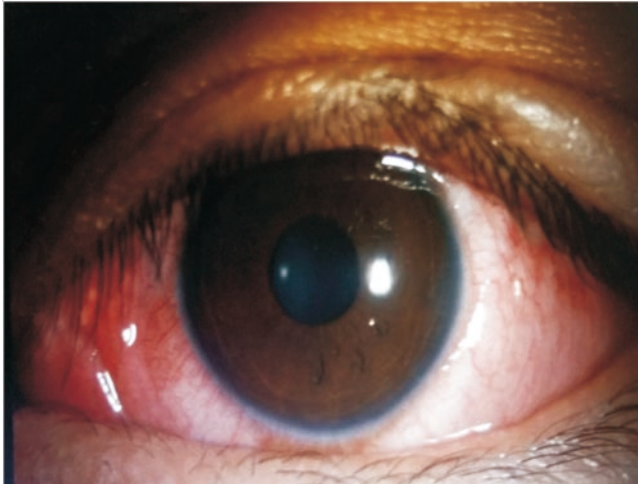


Figure 1. Left eye diffuse chemosis with injected conjunctiva with normal cornea.

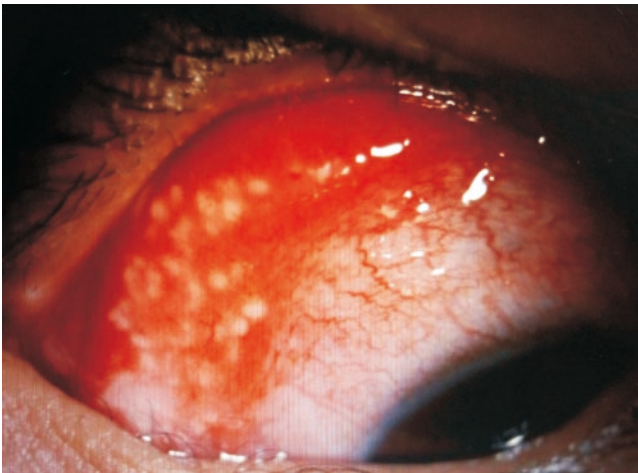


Figure 2. Left eye nasal aspect of bulbar conjunctiva showed multiple creamy white nodular lesion with surrounding erythema.

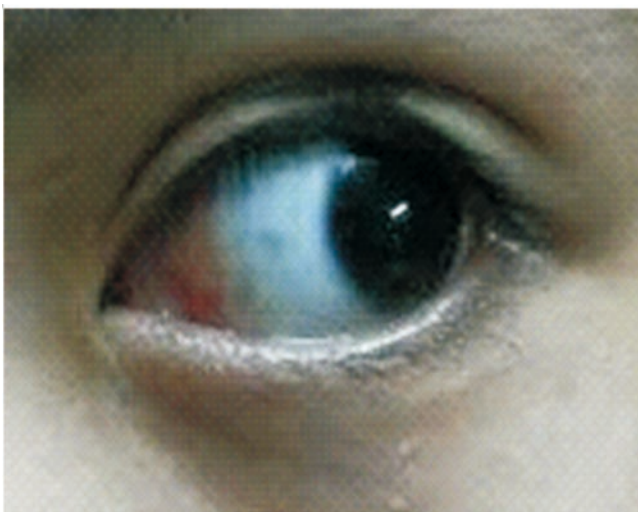

Figure 3. Complete resolution of the left eye nodular like lesion after two weeks of oral ciprofloxacin and moxifloxacin eye drops.

2.2. Case 2

A healthy 37-year-old Malay man presented with 3 weeks history of left eye redness, tearing and watery discharge. He was initially treated with topical maxitrol and moxifloxacin eye drops. Symptoms persisted for more than a week despite topical medication. He was a restaurant worker with a history of contact with cats at his workplace with evidence of few scratches on his toes.

On examination, the left eye vision was fairly good at 6/9. The conjunctiva was diffusely chemotic. There were multiple nodular whitish subconjunctival lesions resembling creamy like abscess over the inferior bulbar conjunctiva (Figure 4). There was also preauricular lymph node swelling of 6 cm in size which was also mildly tender. *B. henselae* serology was not sent due to patient's financial constraint. The presence of characteristic conjunctival lesion with a positive history of cat scratches was highly suggestive of POS. He was treated with 500 mg of oral azithromycin daily. The resolution was very slow which took up to 6 weeks to clear up (Figure 5). Vision remained good at 6/9 over the left eye with complete resolution of the swollen lymph node.

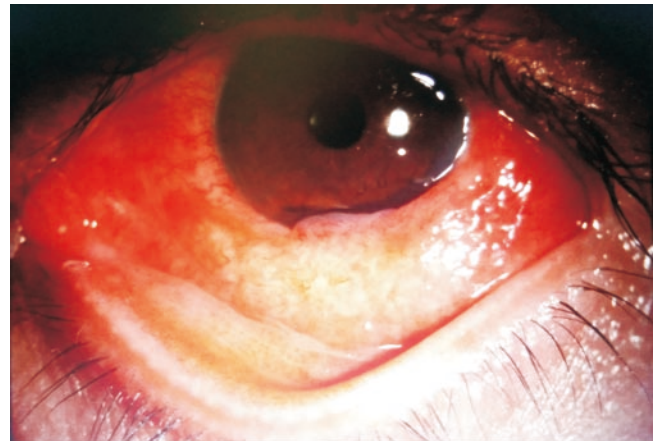


Figure 4. Left eye conjunctiva was diffusely chemotic with granulomatous white creamy like abscess inferiorly.

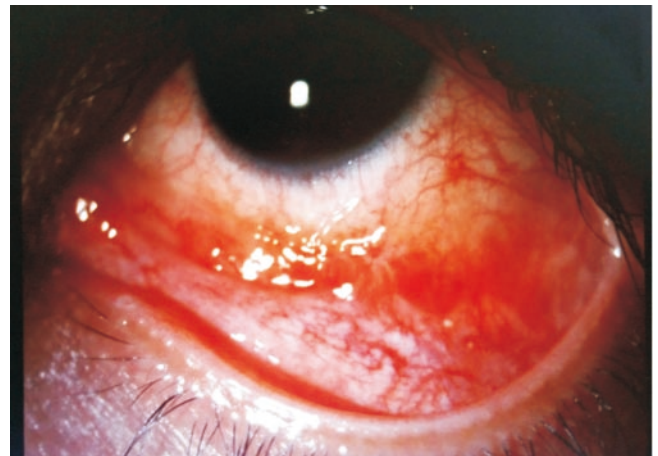


Figure 5. At six weeks review: left eye mild conjunctival redness with resolution of central creamy white abscess.

3. Discussion

POS is described as an atypical form of cat-scratch disease

with granulomatous conjunctivitis and pre-auricular lymph node swelling[1]. The commonest causes for POS are bacterial infections such as *B. henselae*, *M. tuberculosis*, *T. pallidum*, *Francisella tularensis*, *Blastomyces dermatitidis* and *Coccidioides immitis*[2]. Rare causes include infections of *Paracoccidioidomycosis brasiliensis*, herpes simplex virus 1, Epstein-Barr virus, *Pasteurella multocida*, *Yersinia pseudotuberculosis*, *Yersinia enterocolitica*, *Burkholderia mallei*, *Haemophilus ducreyi*, *Rickettsia conorii* and *Listeria monocytogenes*[2].

POS is an atypical presentation of cat-scratch disease which occurs only in 5%–10% of cases[2]. Other ocular presentations of cat-scratch disease are neuroretinitis, vitritis, uveitis, retinitis, choroiditis and retina vascular syndrome[3]. The onset of symptoms to inoculation is 3–10 days[2]. Cat-scratch disease is caused by *B. henselae*, a fastidious Gram-negative rod bacilli[4]. Typically, patients present with lymphadenopathy, malaise, fatigue and fever[3]. Skin lesions of red brown papules could be the initial sign which was absent in our cases[2]. Eyes are infected after skin lesions usually in children less than ten years old[2]. Involvement of the eye with bulbar and palpebral conjunctiva lesions consists of yellowish or whitish granulation tissue surrounded by erythematous margins[2]. Neurological manifestations of cat-scratch disease are rare, which occur in 1%–2% of cases[5]. Gilliaux *et al.*[5] have reported seven cases of atypical cat-scratch disease in children ranging from 14 months to 15 years old with various manifestations and have shown that four out of the seven had history of contact with cats. However, immunoglobulin M was found positive in all cases. Recommended antibiotic treatments were rifampicin, azithromycin, clarithromycin, doxycycline and ciprofloxacin[2]. Domestic cats are the reservoir and transmission is by direct contact with humans by either licking or scratching[3]. Kittens had higher levels of bacteremia and transmitted the disease more effectively than adult cats[6]. Meanwhile, in 2014, Maden *et al.*[7] did an indirect fluorescent test for *B. henselae* on domestic and stray cats and seropositivity was found in 26.88% of domestic cats and 41.94% of stray cats.

Horizontal transmission was also possible via cat flea (*Ctenocephalides felis*) [8]. Cat flea is another transmission vector of *B. henselae*[8]. Cat flea transmission is probably the possible explanation of case 1 who did not have any history of cat scratches.

Laboratory investigation to detect *B. henselae* by indirect fluorescent assay has been reported with sensitivity and specificity of 90%–99%, while ELISA is commercially available with sensitivity of 95%–98%[9]. Lymph node biopsy and Warthin-Starry staining can also be done, while blood culture is usually difficult to yield any positive result[3]. In 2002, Starck and Madsen[9] have reported a case of positive PCR in POS with borderline serology.

POS is commonly self-limiting and recovery can be as early as 3–10 days without treatment[2]. Treatment with antibiotics is advocated to shorten the period of recovery and reduce the risk of injury to other delicate structures[2]. In severe cases such as bacteremia and endocarditis, the use of gentamycin and doxycycline is advocated[10]. The length of treatment for immunocompetent patients is 2–4 weeks while the extension up to four months is

recommended for immunocompromised patients[4]. Both cases in these series were immunocompetent and prolonged for more than 10 days. Hence, antibiotics were given for both cases.

4. Conclusion

POS is a rare presentation of cat-scratch disease. Its prompt recognition and diagnosis help to alleviate unnecessary anxiety related to the underdiagnosis of prolonged granulomatous conjunctivitis among cat lovers. History of contact with cats is one of the strongest positive factors.

Conflict of interest statement

We declare that we have no conflict of interest.

Acknowledgments

Mushawiaht Mustapha had received a fundamental grant from Universiti Kebangsaan Malaysia with the grant number of FF-2016-157.

References

- [1] Yasmeen BN, Jahan RA, Ahmed S, Hussain M, Khan AU, Begum JA, et al. Cat scratch disease – a case report. *North Int Med Coll J* 2013; **5**(1): 316-7.
- [2] Arjmand P, Yan P, O'Connor MD. Parinaud oculoglandular syndrome 2015: review of the literature and update on diagnosis and management. *J Clin Exp Ophthalmol* 2015; doi: 10.4172/2155-9570.1000443.
- [3] Ormerod LD, Dailey JP. Ocular manifestations of cat-scratch disease. *Curr Opin Ophthalmol* 1999; **10**(3): 209-16.
- [4] Roe RH, Michael Jumper J, Fu AD, Johnson RN, Richard McDonald H, Cunningham ET. Ocular bartonella infections. *Int Ophthalmol Clin* 2008; **48**(3): 93-105.
- [5] Gilliaux O, Ghilain V, van der Linden D, Stalens JP, Heijmans C, Louis J, et al. Atypical cat-scratch disease in children: report of seven presentations ranging from hepatosplenic disease to Horner syndrome. *Arch Pediatr Infect Dis* 2016; **4**(1): e28272.
- [6] Acheampong B, Loar RW, Boyce TG. Lymphadenopathy with ipsilateral eye involvement. *Clin Pediatr (Phila)* 2015; **54**: 910-2.
- [7] Maden M, Doğan M, Altuntaş G, Yıldız EE, Ekik M, İnce ME, Köse Sİ. Prevalence of *Bartonella henselae* in pet and stray cats from the aspect of public health: a research sample in the concept of one medicine-one health. *Kafkas Univ Vet Fak Derg* 2015; **21**(3): 313-7.
- [8] Maggi RG, Balakrishnan N, Bradley JM, Breitschwerdt EB. Infection with *Bartonella henselae* in a Danish family. *J Clin Microbiol* 2015; **53**: 1556-61.
- [9] Starck T, Madsen BW. Positive polymerase chain reaction and histology with borderline serology in Parinaud's oculoglandular syndrome. *Cornea* 2002; **21**(6): 625-7.
- [10] Angelakis E, Raoult D. Pathogenicity and treatment of *Bartonella* infections. *Int J Antimicrob Agents* 2014; **44**(1): 16-25.